临床论著

后柱切除后伸压缩中柱矫治胸腰段骨质疏松性重度椎体压缩骨折伴后凸畸形

李 超,于海洋,付青松,周 宇,赵 刚,尹 稳,兰魁勇
(安徽省阜阳市人民医院骨科 236003 安徽省阜阳市鹿祠街 63 号)

【摘要】目的:评价后柱切除后伸压缩中柱矫治胸腰段骨质疏松性重度椎体压缩骨折伴后凸畸形的安全性和临床效果。方法:2009 年 7 月~2012 年 1 月经后入路行后柱切除后伸压缩中柱矫治胸腰段骨质疏松性重度椎体压缩骨折伴后凸畸形患者 14 例,男 2 例,女 12 例;年龄 62~81 岁,平均 68 岁。骨折均位于 T11~L2,其中单椎体骨折 12 例,两个椎体骨折 2 例;椎体高度压缩 78.5%~92.4%,平均 82.5%。后凸畸形的顶椎均位于胸腰段,其中 L1 7 例,T12 5 例,L2 2 例。后凸畸形 Cobb 角 39°~59°,平均 45°;脊柱矢状位 C7 铅垂线偏移距离为 0.4~2.8cm,平均 1.6cm;腰椎前凸 41°~62°,平均 58.4°,9 例出现腰椎前凸代偿性加大。均有腰背部疼痛及疲劳感,疼痛视觉模拟评分(VAS)8.5 分(7.5~9 分)。神经功能按 Frankel 分级:E 级 12 例,D 级 2 例。其中 10 例采用注射型聚甲基丙烯酸甲酯骨水泥强化钉道。结果:手术时间 187~221min,平均 190min;术中出血量 372~463ml,平均 420ml。1 例术中硬脊膜破裂,予以修补,术后未发生脑脊液漏。术后胸腰椎后凸 Cobb 角 0°~9°,平均 5°,平均矫正率达 88.9%;矢状位 C7 铅垂线偏移距离 0~0.8cm,平均 0.3cm;腰椎前凸角 28°~43°,平均 37°。随访 12~33 个月,平均 21 个月。末次随访时,胸腰椎后凸 Cobb 角 0~11°,平均 7°;矢状位 C7 铅垂线偏移距离为 0~1.2cm,平均 0.4cm;腰椎前凸 29°~45°,平均 39°;神经功能按 Frankel 分级均为 E 级;腰背疼痛消失 11 例,明显缓解 3 例,VAS 为 1.9(0~3.5)分,与术前比较差异有统计学意义($P<0.05$);均植骨融合及骨折愈合良好,内固定无松动及拔出,固定邻近节段无继发骨折。结论:后柱切除后伸压缩中柱矫治胸腰段骨质疏松性重度椎体压缩骨折伴后凸畸形,与经椎弓根截骨术比较手术操作简单、创伤小。当骨质疏松性重度椎体压缩骨折伴后凸难以施行椎体成形术时,此技术是一种安全有效的补充方法。

【关键词】重度椎体压缩骨折;后凸畸形;骨质疏松;后柱切除;中柱压缩
doi:10.3969/j.issn.1004-406X.2013.08.06
中图分类号:R682.3,R683.2 文献标识码:A 文章编号:1004-406X(2013)-08-0700-06

Posterior column resection followed by extension and middle column compression for thoracolumbar severe osteoporotic vertebral compressive fractures combined with kyphosis/LI Chao, YU Haiyang, FU Qingsong, et al//Chinese Journal of Spine and Spinal Cord, 2013, 23(8): 700-705

【Abstract】**Objectives:** To evaluate the clinical outcome and safety of posterior column resection plus middle column compression for thoracolumbar kyphosis caused by severe osteopororotic compressive vertebral fractures. **Methods:** From July 2009 to January 2012, 14 patients suffering from thoracolumbar kyphosis caused by severe osteopororotic compressive vertebral fractures were treated with posterior column resection followed by extension and middle column compression. There were 2 males and 12 females with an average age of 68 years (range, 62-81 years). All the fractured vertebral located at T11-L2, 12 patients had one vertebral involvement and 2 had two levels. The rate of loss of vertebral height ranged from 78.5% to 92.4%(mean, 82.5%). The apical vertebral located at L1 in 7 cases, T12 in 5 cases and L2 in 2 cases. The mean preoperative kyphosis Cobb angle was 45°(range, 39°-59°). The distance between the C7 plumb line and the center sacral line was 1.6cm on average(range, 0.4-2.8cm). The preoperative lumbar lordosis was 41°-62°(mean, 58.4°), of them, 9 cases had compensatory lumbar lordosis. All the 14 patients presented with low back pain with an average preoperative visual analogue score(VAS) of 8.5(range, 7.5-9). According to Frankel classification, there were 12 grade E and 2 grade D. 10 patients underwent bone cement augmentation surgery. **Results:** The average

第一作者简介:男(1955-),主任医师,教授,博士生导师,研究方向:脊柱外科
电话:(0558)2515266 E-mail:fylichao2008@sina.com

surgical time was 190 minutes(range, 187–221 minutes). The average blood loss was 420ml(range, 372–463ml). The dura tearing occurred in 1 case. The postoperative average thoracolumbar kyphosis Cobb angle was 5° (range, 0–9°) with a 88.9% correction rate and the sagittal imbalance was corrected to 0.3cm(range, 0–0.8cm). The postoperative lumbar lordosis ranged from 28° to 43°(mean, 37°). The mean follow-up period was 21 months(range, 12–33 months). The average thoracolumbar kyphosis Cobb angle was 7°(range, 0–11°). The sagittal imbalance was 0.4cm(range, 0–1.2cm). The lumbar lordosis ranged from 29° to 45°(mean, 39°). 2 patients with Frankel grade D had recovered to grade E. The average VAS score was significantly improved to 1.9(range, 0–3.5) after surgery. The back pain relieved completely in 11 patients and partially in 3 patients. Bony fusion was achieved in all patients with no instrument related complication. **Conclusions:** Posterior column resection followed by extension and middle column compression is a reliable treatment for thoracolumbar kyphosis caused by severe osteopororotic compressive vertebral fractures. It is simple and less invasive compared with transpedicular osteotomy, and can be used as an alternative in cases where PVP is not suited.

【**Key words**】Severe vertebral compressed fracture; Kyphosis; Osteoporosis; Posterior column resection; Middle column compression

【**Author's address**】Department of Orthopaedics, Fuyang People's Hospital, Anhui, 236003, China

骨质疏松性椎体骨折保守疗法效果不佳，部分患者由于长期卧床而出现肺部、泌尿系感染等严重并发症而死亡，5 年病死率高达 23%~34%[1]。由于患者骨质质量差，难以通过常规的脊柱内固定获取良好的复位及固定效果。近年来，采用经皮椎体成形术治疗骨质疏松性椎体压缩骨折，可迅速重建伤椎强度和部分恢复椎体高度，迅速止痛，使患者能早期下地活动，显著提高患者的生活质量，已成为目前治疗骨质疏松性椎体骨折理想的手段[2,3]。但对骨质疏松性重度椎体压缩骨折（osteoporotic severe vertebral compression fracture，OSVCF）采用经典的经椎弓根穿刺入路往往难以经椎弓根到达伤椎前、中柱，无法建立合理有效的穿刺通道而完成椎体成形术。由于技术操作相对困难，Deramond 等[4]认为此类骨折是椎体成形术的手术禁忌证。因此，治疗 OSVCF 伴后凸畸形已成为目前脊柱外科的难题之一。2009 年 7 月~2012 年 1 月我们采用经后入路行后柱切除后伸压缩中柱矫治 OSVCF 伴后凸畸形患者 14 例，报道如下。

1 资料与方法

1.1 一般资料

本组男 2 例，女 12 例；年龄 62~81 岁，平均 68 岁。骨密度 T 值为–2.9~–4.5，平均–3.7。骨折均位于胸腰段（T11~L2），其中单椎体骨折 12 例（L1 6 例，T12 4 例，L2 2 例），两个椎体骨折 2 例（L1、L2 1 例，T12、L11 例）。椎体高度压缩 78.5%~92.4%，平均 82.5%。后凸畸形的顶椎均位于胸腰段原骨折椎体，其中 L1 7 例，T12 5 例，L2 2 例。脊柱矢状位 C7 铅垂线偏移距离为 0.4~2.8cm，平均 1.6cm。腰椎前凸 41°~62°，平均 58.4°。临床表现：（1）腰背痛 14 例，术前疼痛视觉模拟评分（VAS）8.5 分（7.5~9 分）；（2）躯干失去支撑引起腰背部疲劳感 14 例；（3）站立姿态前倾 11 例；（4）9 例出现腰椎前凸代偿性增大；（5）胸腰段脊柱后凸畸形 14 例，后凸畸形 Cobb 角 39°~59°，平均 45°；（6）因腰背痛、疲劳需要扶拐行走者 9 例。神经功能按 Frankel 分级：E 级 12 例，D 级 2 例。

1.2 手术方法

均采用经后入路行后柱切除后伸压缩中柱椎弓根钉棒固定植骨融合术矫治 OSVCF 伴后凸畸形。选择气管插管全麻，体表感觉诱发电位监测。取俯卧位，后正中切口，根据术前融合固定范围确定切口长度，显露脊柱后部结构，于截骨远、近端分别安置 2~3 个节段椎弓根螺钉（通常为 4 组）。对于椎弓根螺钉固定强度欠佳者，采用骨水泥强化钉道。对后凸顶椎实行后柱切除术，椎板上下切除范围根据后凸畸形程度、病变部位等情况确定。椎板楔形截骨，尖部朝向顶椎椎体前缘，底部位于顶椎后方椎板。切除棘突、椎板、关节突和横突，显露脊髓及椎弓根。分别切除两侧椎弓根及椎弓根基底部皮质骨，椎弓根与椎体结合部的皮质骨较为坚硬，可用磨钻将其打磨去除。椎体及椎体后壁不需要切除，仅用 L 型凿对椎体后壁打压，使椎体后壁断裂并下沉陷入椎体内 3~5mm。调整手术

台,使脊柱逐渐后伸,于胸椎左、右两侧分别安装预弯的固定棒并与椎弓根螺钉连接,然后逐渐压棒,加压闭合后柱截骨间隙。最后将固定棒远端与腰椎椎弓根螺钉连接固定,进一步加压闭合后柱截骨间隙(图 1、2)。将固定范围内的椎板、关节突、横突区去皮质化,将后柱切除的骨质和椎板去皮质化翻转的骨皮质行后路自体植骨。术后负压引流 48h,2 周后佩戴支具下床活动,应用支具 6 个月。

2 结果

固定节段 5~6 个,平均 5.8 个节段。10 例钉道采用注射型聚甲基丙烯酸甲酯骨水泥(Heraeus Medical 公司,德国)强化。手术时间 187~221min,平均 190min。术中出血量 372~463ml,平均 420ml。1 例术中硬脊膜破裂,予以修补,术后未发生脑脊液漏。术后胸腰椎后凸 Cobb 角 0°~9°,平均 5°,平均矫正率达 88.9%;矢状位偏移距离 0~0.8cm,平均 0.3cm;腰椎前凸角 28°~43°,平均 37°。随访 12~33 个月,平均 21 个月。末次随访时,神经功能按 Frankel 分级均为 E 级;腰背疼痛消失 11 例,明显缓解 3 例,VAS 为 1.9(0~3.5)分,与术前比较差异有统计学意义($P<0.05$);所有患者躯干前倾消失,腰椎代偿性前凸消失;腰背部疲劳

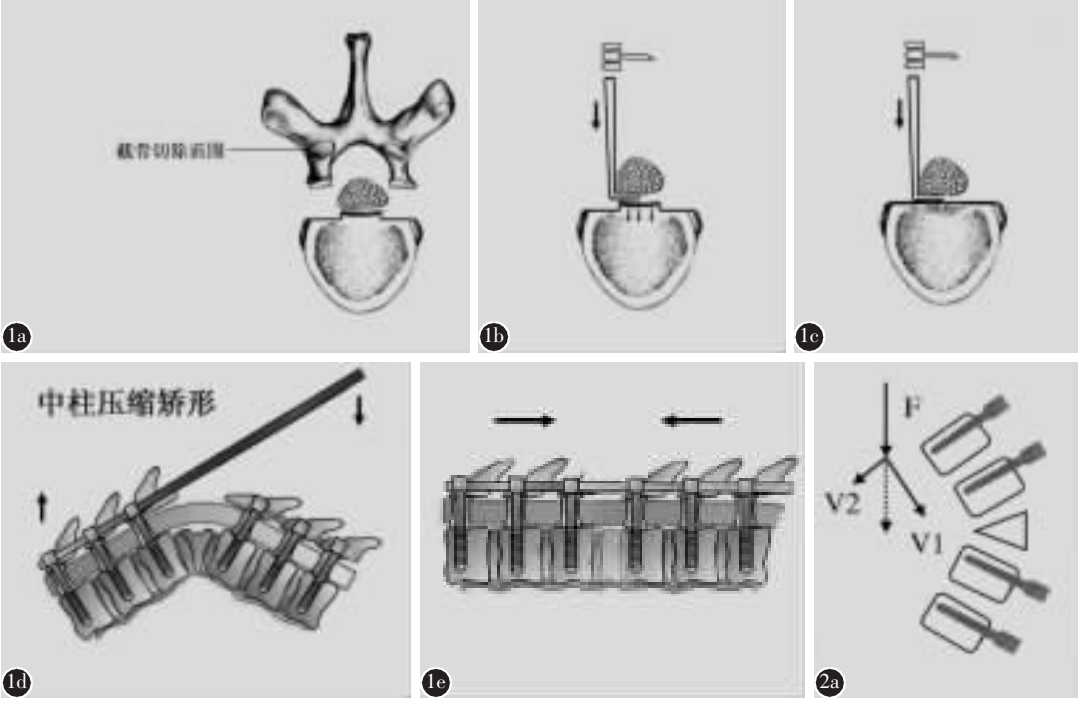

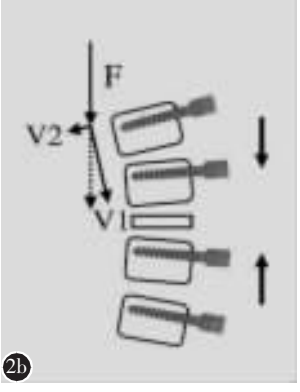

图 1 a 后柱切除范围包括:棘突、椎板、横突、椎弓根及椎弓根与椎体结合部的皮质骨 b、c L 型凿打压椎体后壁 **d** 压缩中柱矫形 **e** 后柱加压闭合 **图 2** 后柱切除后伸压缩中柱矫治骨质疏松性重度椎骨折伴后凸示意图 **a** 矫正前示意图:F=V1+V2,F 为顶椎以上的躯干负重力,V1 脊柱中轴方向的矢量,V2 是 F 分解出向躯干腹侧前下方的剪切力 **b** 矫正后示意图,V2 减小

Figure 1 a posterior column resection, the cortical bone in the binding portion of the pedicle and vertebral was removal compressed **b** The range of osteotomy resection **c** The vertebral posterior wall was suppressed by L burr **d** Kyphosis was corrected by compressing middle column **e** Posterior column was closed with compression **Figure 2** The schematic diagram of posterior column resection extension and middle column compression for severe osteoporotic vertebral fractures with kyphosis **a** The schematic diagram before correction; F=V1+V2; F, vertical load to the thoracic spine; V1, vector in the axial direction; V2, vector that pushes the thoracic spine inferio-ventrally **b** The schematic diagram after correction. V2, decrease

感消失;行走不需扶拐;胸腰椎后凸 Cobb 角 0°~11°, 平均 7°; 矢状位 C7 铅垂线偏移距离为 0~1.2cm, 平均 0.4cm; 腰椎前凸 29°~45°, 平均 39°; 所有患者植骨融合及骨折愈合良好, 内固定无松动及拔出, 固定邻近节段未见继发骨折(图 3、4)。

3 讨论

3.1 骨质疏松性椎体压缩骨折治疗方法的选择

OSVCF 是老年人的常见病和多发病, 可导致患者腰背部持续性疼痛, 脊柱后凸畸形和活动减少, 长期卧床, 严重影响患者的呼吸及消化功能, 降低生活质量。传统的治疗方法包括卧床休息、支具保护及药物疗法, 但多难以缓解顽固性腰背痛, 治疗效果并不理想。卧床不仅加速骨量丢失, 且易并发泌尿系感染、肺部感染及褥疮等并发症, 同时又增加了再骨折的风险。脊柱后凸畸形、疼痛的加重导致胸腔容积缩小、心肺功能下降、死亡率明显增高。由于椎体骨质疏松, 椎弓根螺钉等内置物难以在椎体内获得满意把持力, 手术复位与内固定常不能获得理想效果。经皮椎体成形术是近年来脊柱外科领域中兴起的一种新型微创术式。近年来该技术广泛应用于治疗老年骨质疏松性椎体压缩骨折, 技术简单、微创, 且能增加椎体的强度、使伤椎高度完全或部分恢复, 以矫正后凸畸形, 止痛效果显著, 有效率达到 95%以上[2,3]。但对于椎体压缩>75%的 OSVCF, 采用经典的经椎弓根穿刺入路往往难以经椎弓根到达伤椎前、中柱而建立合理有效的穿刺通道而完成椎体成形。椎体成形术治疗 OSVCF, 由于穿刺针很难到达理想位置, 且球囊容易将骨质胀破, 注射骨水泥易发生渗漏, 导致严重并发症[5,6]。有学者报道椎间骨水泥渗漏可以引起周围终板及椎间盘塌陷, 导致椎体间不稳和相邻椎体新的压缩性骨折[7,8]。戈朝晖等[6]采用单侧经椎弓根外穿刺入路行椎体后凸成形术治疗 OSVCF 患者 22 例, 术后椎体前、中柱高度比术前略有恢复, 但差异无统计学意义, 手术前后骨折椎体后凸角度对比无统计学意义。近年来, 尤其在治疗成人脊柱畸形的研究中, 脊柱矢状面平衡对

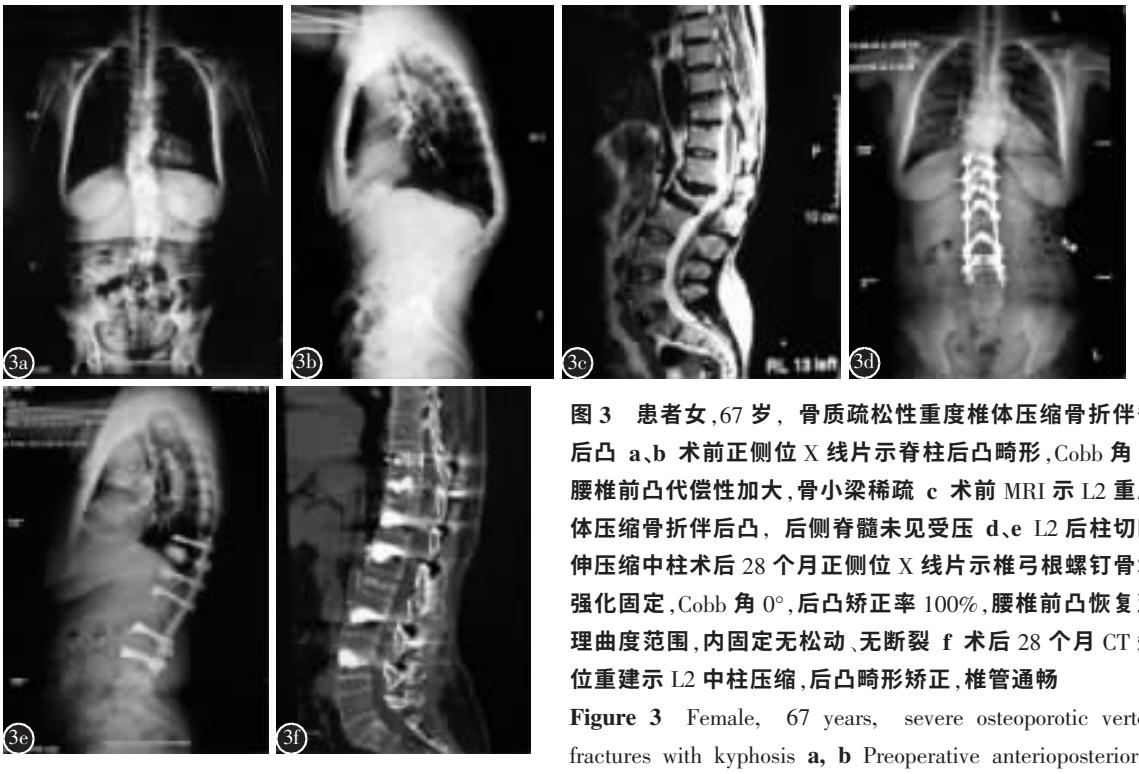

图 3 患者女, 67 岁, 骨质疏松性重度椎体压缩骨折伴脊柱后凸 **a、b** 术前正侧位 X 线片示脊柱后凸畸形, Cobb 角 47°, 腰椎前凸代偿性加大, 骨小梁稀疏 **c** 术前 MRI 示 L2 重度椎体压缩骨折伴后凸, 后侧脊髓未见受压 **d、e** L2 后柱切除后伸压缩中柱术后 28 个月正侧位 X 线片示椎弓根螺钉骨水泥强化固定, Cobb 角 0°, 后凸矫正率 100%, 腰椎前凸恢复至生理曲度范围, 内固定无松动、无断裂 **f** 术后 28 个月 CT 矢状位重建示 L2 中柱压缩, 后凸畸形矫正, 椎管通畅

Figure 3 Female, 67 years, severe osteoporotic vertebral fractures with kyphosis **a, b** Preoperative anterioposterior and lateral X-ray showed kyphosis Cobb angle of 47°, lumbar lordosis compensatory increase and the vertebral trabecular bone sparse **c** Preoperative MRI showed L2 severe osteoporotic vertebral fractures with kyphosis and no compression of posterior spinal cord **d, e** 28 months after surgery, radiograph showed that the kyphosis was corrected completely with no kyphosis, the lumbar spin recovered to the physiological curvature and no instrument complication was documented **f** 28 months after surgery, the CT sagittal reconstruction showed: the kyphosis was corrected, the spinal canal showed no compression and compression of the middle column

图 4 患者女,79 岁,骨质疏松性重度椎体骨折伴脊柱后凸及双下肢麻木,Frankel D 级 **a、b** 术前正侧位 X 线片示脊柱后凸畸形,Cobb 角 59°,腰椎前凸代偿性加大,骨小梁稀疏 **c** 术前 MRI 示 T12、L1 重度椎体压缩骨折伴后凸,后侧脊髓未见受压 **d、e** T12 后柱切除后伸压缩中柱术后 33 个月正侧位 X 线片,侧位片示 Cobb 角 0°,后凸矫正率 100%,腰椎前凸恢复至生理曲度范围,内固定无松动、无断裂 **f** 术后 33 个月 MRI 示 T12 中柱压缩,后凸畸形矫正,椎管通畅

Figure 4 Female, 79 years, severe osteoporotic vertebral fractures with kyphosis and numbness of lower limbs(Frankel D) **a, b** Preoperative anterioposterior and lateral X-ray showed kyphosis Cobb angle of 59°, lumbar lordosis compensatory increase and the vertebral trabecular bone sparse **c** Preoperative MRI showed T12 and L1 severe osteoporotic vertebral fractures with kyphosis and no compression to the posterior spinal cord **d, e** 33 months after surgery, radiography showed that the kyphosis was corrected completely with no kyphosis, the lumbar recovered to the physiological curvature from preoperative compensatory lordosis and no instrument complication was documented **f** 33 months after surgery, MRI showed the kyphosis was corrected, the spinal canal showed no compression and compression of the middle column

治疗效果的影响逐渐受到学者的重视。成人脊柱畸形患者的生存质量和冠状面畸形关系不大,但与矢状面畸形却密切相关,轻度的矢状面失衡即会引起生存质量的改变,且失衡的程度与生存质量的恶化呈线性关系[9,10]。老年 OSVCF 伴后凸畸形患者后凸顶椎以上的躯干负重力(F)线发生异常改变,产生向躯干前下方剪切力(V2),导致矢状面失衡(图 2a),引起患者背部疲劳和疼痛。对于 OSVCF,目前尚无理想的治疗方法。治疗 OSVCF 伴后凸畸形是目前脊柱外科领域的难点之一。

3.2 手术安全性及疗效分析

对 OSVCF 伴后凸畸形,采用保守治疗、切开复位内固定及椎体成形术等,均难以达到满意疗效。Saita 等[11]报道采用后柱缩短截骨治疗 OSVCF,获得了良好的手术效果。但该手术经椎弓根截骨,手术时间长,创伤大,出血多,平均手术时间为 279min,出血量平均 917g(875ml)。另外,经椎弓根截骨术暴露范围大,游离和切除椎体后缘骨壁及椎体难度大,出血多,稍有不慎可导致脊髓损伤。尤其老年骨质疏松患者,身体条件差,合并疾病多,术中切除椎体容易发生难以控制的大量出血,手术并发症多。我们采取椎体后柱切除后伸压缩中柱矫治 OSVCF,平均手术时间仅 190min,出血量平均 420ml,手术时间及出血量明显小于 Saita 报道的经椎弓根截骨技术。我们认为椎弓根是椎体最坚固的部位,堪称“椎体力核”,是支撑椎体的核心结构,一旦切除椎弓根及椎弓根与椎体结合部的皮质骨,椎体的中柱和后柱支撑核心结构被去除,有利于后部截骨闭合矫形。我们设计的后路改良楔形截骨术仅切除了椎板、横突、椎弓根及椎弓根基底部的皮质骨,而对椎体和椎体后壁不作切除,仅用 L 型凿对椎体后壁打压,使疏松的椎体后壁骨折并压缩至椎体内。利用椎体骨质疏松、强度降低及便于压缩的特点,以中柱作为压缩支点,对患者采取后伸复位和钉棒杠杆压缩矫

形的方法,在后部截骨加压闭合过程中,中柱被逐渐压缩,致使严重塌陷的前柱与压缩闭合的中柱和后柱重新建立了三柱平衡,矫正了后凸,减少了向躯干前下方的剪切力(V2)(图 2b),有效预防腰背部疲劳和疼痛。本组患者术后末次随访腰背部疲劳感消失;行走不需扶拐;腰背疼痛 11 例消失,3 例明显缓解,末次随访时 VAS 为 1.9(0~3.5),与术前比较差异有统计学意义 (P<0.05);2 例神经功能障碍患者由 Frankel D 级恢复到 E 级。与经椎弓根截骨术相比,此手术由于不切除椎体和椎体后壁,手术显露简便,手术时间短,创伤相对较小,出血少,安全性好。另外,在后柱截骨加压闭合矫正过程中,脊柱逐渐后伸并向前成角折顶复位,此时压缩的椎体后壁只会向前成角移位,不会对脊髓构成压迫的风险。本组未发生神经受压并发症。由于椎体骨质疏松,为增加椎弓根螺钉在椎体内的把持力,我们对严重椎体骨质疏松者实行椎弓根螺钉骨水泥强化,较好地解决了手术内固定松动问题。本组所有患者植骨融合及骨折愈合良好,内固定无松动及拔出。严重骨质疏松患者,由于融合率低及应力集中,内固定失败及邻近节段继发骨折的发生率较高,本组因随访时间较短,尚未发生上述并发症,长期疗效需继续随访观察。

3.3 手术指征

截骨手术治疗骨质疏松性脊柱压缩骨折伴后凸畸形,对于高龄人群来说是高侵入性的,且可能发生严重并发症,应谨慎选择[11]。骨质疏松性椎体压缩骨折遇到下列情况之一者有本手术矫正指征:(1)椎体高度压缩>75%,椎体失去支撑功能,导致前纵韧带松弛,在顶椎区域形成假关节样现象,引起顶椎区域疼痛;(2)后凸 Cobb 角>30°的不稳定的畸形(其危害是畸形进行性加重和神经损害[12]);(3)后凸不断发展,脊髓慢性受压,脊髓明显变扁,引起组织学改变,包括脱髓鞘和神经元丢失,脊髓因受到纵向牵张可继发迟发性瘫痪[13,14]。对于椎管内有椎间盘突出或骨赘压缩脊髓者为本手术禁忌证。

综上所述,后柱切除后伸压缩中柱矫治 OSVCF 伴后凸畸形,手术操作简便,创伤小。当 OSVCF 伴后凸畸形难以行椎体成形术时,选择本技术是一种安全有效的补充方法。

4 参考文献

1. Kado DM, Duong T, Stone K L, et al. Incident vertebral fractures and mortality in older women: a prospective study[J]. Osteoporosis Int, 2003, 14(7): 589–594.
2. Kasper DM. Kyphoplasty[J]. Semin Intervent Radiol, 2010, 27 (2): 172–184.
3. Farrokhi MR, Alibai E, Maghami Z. Randomized controlled trial of percutaneous vertebroplasty versus optimal medical management for the relief of pain and disability in acute osteoporotic vertebral compression fractures[J]. J Neurosurg Spine, 2011, 14 (5): 561–569.
4. Deramond H, Derpriester C, Galibert P, et al. Percutaneous ve–rtebroplastywith polymethylmethacrylate: technique,indications, and results[J]. Radiol Clin North Am, 1998, 36(3): 533–546.
5. Jarvik JG, Kallmes DF, Mirza SK. Vertebroplasty learning more, but not enough[J]. Spine, 2003, 28(14): 1487–1489.
6. 戈朝晖, 丁惠强, 梁思敏, 等. 单侧椎弓根外入路椎体后凸成形术治疗重度骨质疏松性椎体骨折[J]. 第三军医大学学报, 2011, 33(17): 1868–1871.
7. Nagad P, Rawall S, Kundnani V, et al. Postvertebroplasty instability[J]. J Neurosurg Spine, 2012, 16(4): 387–393.
8. Rho YJ, Choe WJ, Chun YI. Risk factors predicting the new symptomatic vertebral compression fractures after percutaneous vertebroplasty or kyphoplasty[J]. Eur Spine J, 2012, 21(5): 905–911.
9. Glassman S, Bridwell K, Dimar J, et al. The impact of positive sagittal balance in adult spinal deformity[J]. Spine, 2005, 30(18): 2024–2029.
10. Schwab F, Smith V, Biserni M, et al. Adult scoliosis: a quantitative radiographic and clinical analysis[J]. Spine, 2002, 27(4): 387–392.
11. Saita K, Hoshino Y, Higashi T, et al. Posterior spinal shortening for paraparesis following vertebral collapse due to osteoporosis[J]. Spinal Cord, 2008, 46(1): 16–20.
12. 邱勇, 朱锋, 钱邦平, 等. 胸腰椎骨折术后并发迟发性后凸畸形的危险因素和后路脊柱短缩术[J]. 中华创伤杂志, 2006, 22(1): 11–15.
13. Shimizu K, Nakamura M, Nishikawa Y. Spinal kyphosis causes demyelination and neuronal loss in the spinal cord: a new model of kyphotic deformity using juvenile Japanese small game fowls[J]. Spine, 2005, 30(21): 2388–2392.
14. Song KS, Chang BS, Yeom JS, et al. Surgical treatment of severe angular kyphosis with myelopathy: anterior and posterior approach with pedicle screw instrumentation [J]. Spine, 2008, 33(11): 1229–1235.

(收稿日期:2013–02–28 末次修回日期:2013–05–05)

(英文编审 蒋 欣/党 镭)

(本文编辑 李伟霞)